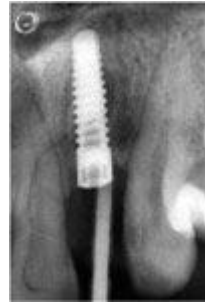
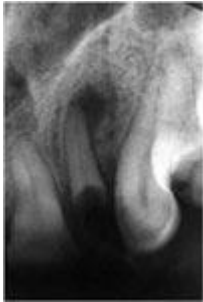


● Dr. Radu Baston ●

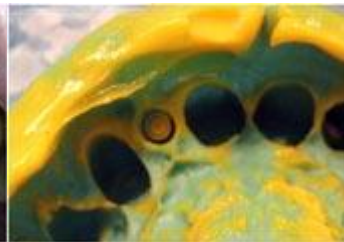
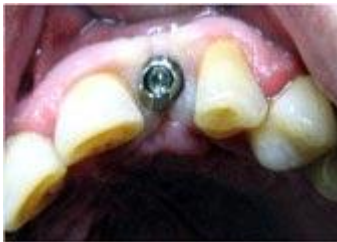Patient no. 1

Single Tooth Replacement 22



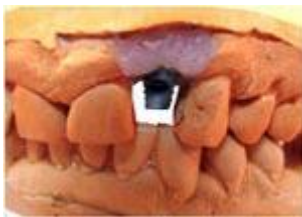1. Tooth removal 22
2. Cyst enucleation through the alveolus
3. Immediate implant placement (16mm length, 3,7mm diameter)

No G. T. R.!

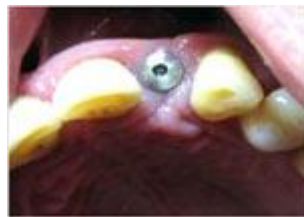

Non-standard closed-tray Impression Technique

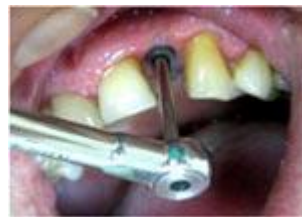Master cast and abutment insertion



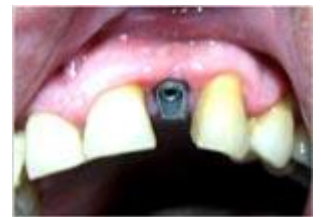1. Angulated abutment on master cast



2. Healing cylinder featuring a natural emergency profile from 3.7 to 4.8mm



3,4. The sand-blasted abutment is fastened into the implant with a 35Ncm. torque



An indirect composite crown has been cemented directly on the abutment following an adhesive protocol

