




● Dr. Radu Baston ●

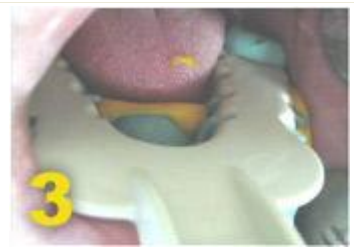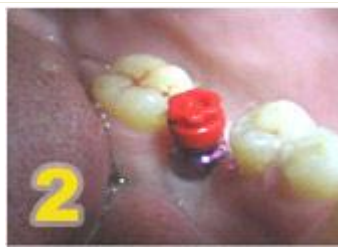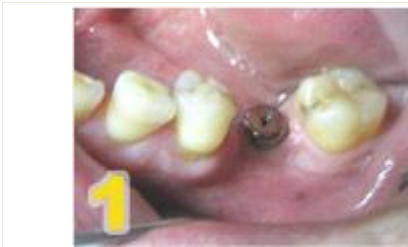Patient no. 2

Single Tooth Replacement 36

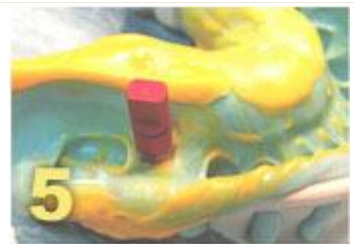
Initial examination



Fracture of the ceramic cusp forced me to cut off the cemented crown and the damaged abutment.



Closed-tray Impression technique
= "pop-in" = "reposition"
technique"



Adjusting the abutment shoulder on the master cast



INITIAL BUCCAL VIEW

INITIAL OCCLUSAL VIEW

FINAL LINGUAL VIEW

FINAL BUCCAL VIEW

THE LINGUAL ASPECT OF THE SHOULDER HAS RETAINED ITS ORIGINAL SHAPE

THE BUCCAL SHOULDER HAS BEEN MODIFIED


The crown is cured directly on the abutment for cemented superstructures



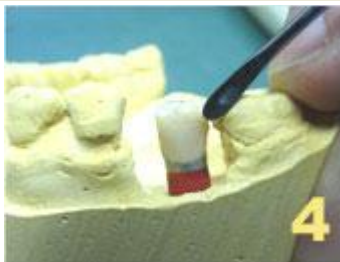1



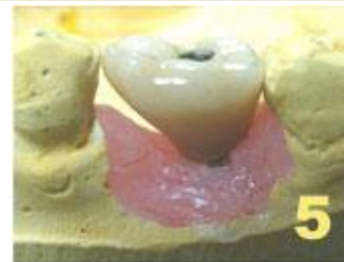2



3

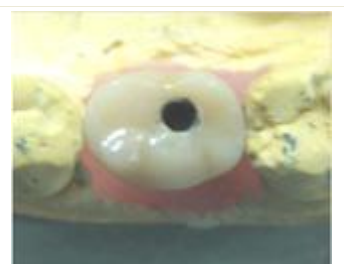
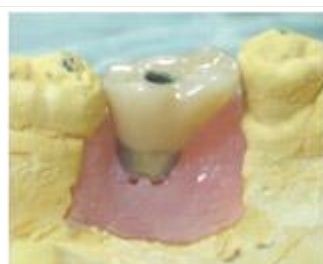
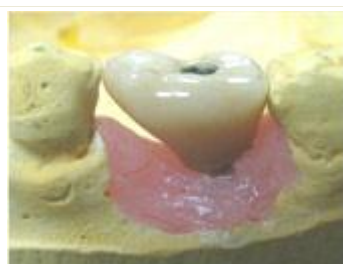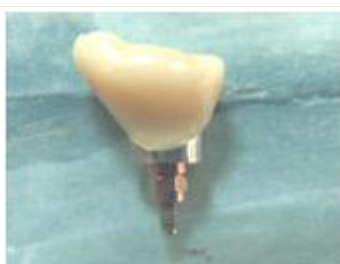4



5

The crown design: no gap, no cementation, customized slanted step, screw-retained.



Crown fastening and final result

